

# VACUUM CLEANER INJURY TO PENIS: A COMMON UROLOGIC PROBLEM?

RALPH C. BENSON, JR., M.D.

From the Department of Urology, Mayo Clinic and  
Mayo Foundation, Rochester, Minnesota

---

*ABSTRACT—Erotic stimulation by the use of vacuum cleaners or electric brooms appears to be a common form of masturbation. Unfortunately, and contrary to apparent public appreciation, injury due to this form of autostimulation may not be unusual. Five cases of significant penile trauma resulting from this form of masturbation are presented, with a spectrum of severe injuries, including loss of the glans penis.*

---

Most civilian penile injuries occur in industrial, farm, or automobile accidents, in athletic contests, or as a result of attempts at self-mutilation.<sup>1-9</sup> Occasional unusual accidental injuries sustained from such objects as zippers, string, hair, rubber bands, and toilet seats have also been recorded.<sup>10-16</sup> In addition, many forms of penile injury have been described after attempts at erotic stimulation, strangulation by encircling rings being the most common.<sup>17-19</sup> Experience with patients who suffered severe penile injury by autostimulation with vacuum cleaners prompted review of this reportedly unusual problem.

## Case Reports

### Case 1

A seventeen-year-old male student presented with penile and urethral injuries sustained during masturbation with an electric broom. Injuries included a complete circumferential skin laceration 0.5 cm proximal to the coronal sulcus, laceration of the urethra, and laceration of the glans penis, penetrating all the way through to the urethra. A suprapubic cystostomy was performed, and the lacerations were repaired. The urethral laceration was repaired in three layers over an 18-F Foley catheter. The urethral catheter was removed in two days and the suprapubic cystostomy tube in ten days.

The postoperative result was cosmetically satisfactory except for minimal deformity of the left side of the glans penis. The patient experienced a stricture in the bulbous urethra ten years later which was successfully treated by internal urethrotomy.

### Case 2

A fifty-one-year-old man, a "recovering alcoholic," sustained penile injury during autostimulation with a vacuum cleaner. Examination of the penis revealed a completely avulsed (and missing) glans penis; a portion of the distal urethra was missing. For treatment, the skin was closed over the exposed corpora cavernosa and a hypospadiac meatus was created in the area of the midshaft of the penis. Two months postoperatively, meatal stenosis was noted and was easily dilated from 16 F to 28 F. The patient maintains this meatal caliber himself by means of a meatal dilator.

### Case 3

An eighteen-year-old male student was seen in the emergency room with severe penile lacerations and profuse bleeding sustained while masturbating with an electric broom. The patient was given 2 units of whole blood. Examination of the penis in the operating room

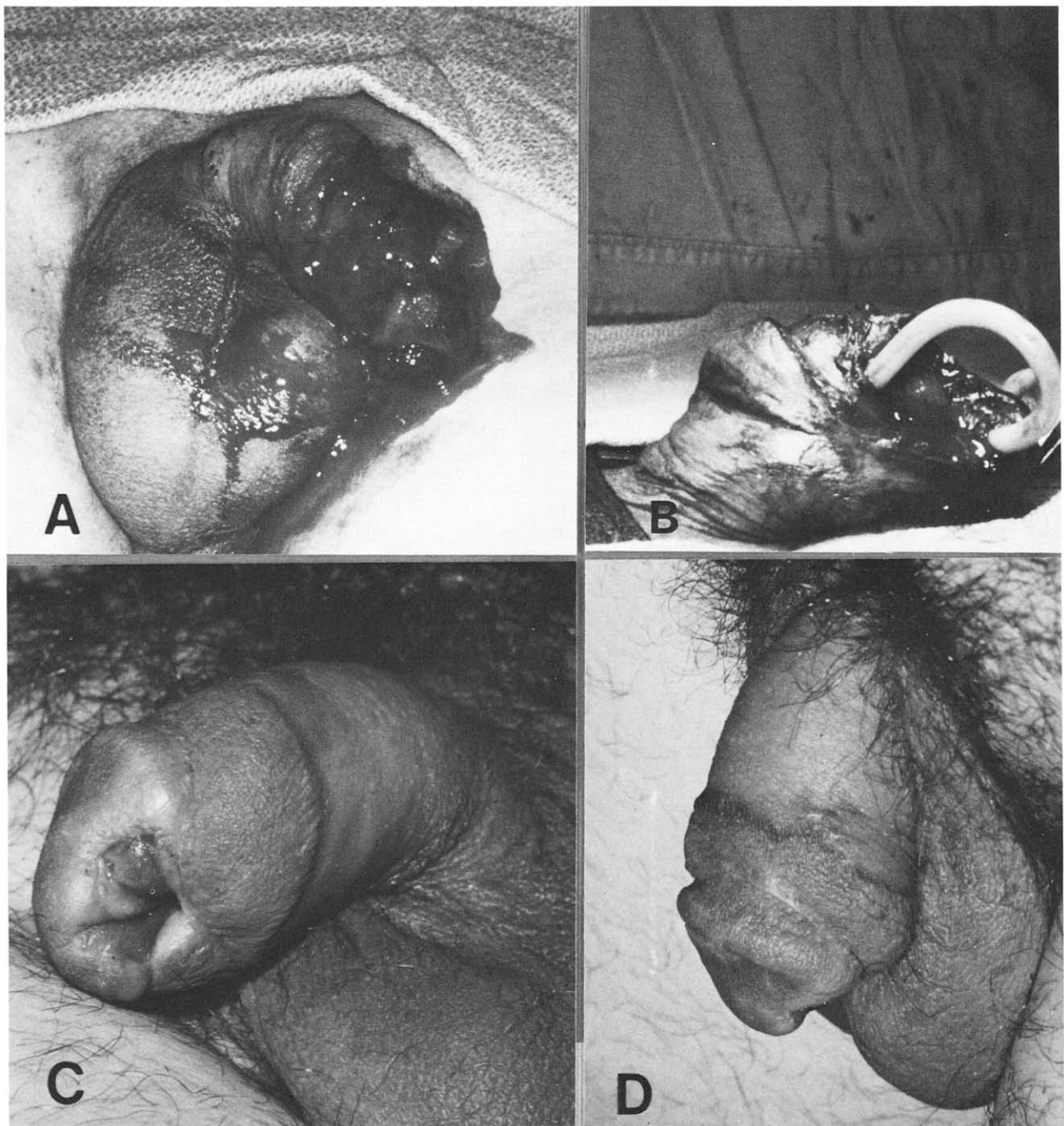


FIGURE 1. (Case 3). (A) Extensive circumferential lacerations of penis. (B) Catheter placed in urethral meatus exits completely transected urethra before entering more proximal urethral stump. Glans penis is attached to remainder of penis and by bridge of corpus spongiosum. (C and D) Ventral and lateral views, respectively, of postoperative result. Wedge of glans penis has sloughed, leaving slightly hypospadiac urethral meatus.

revealed extensive laceration of the penile skin; avulsion of the glans penis, which remained attached only by a small bridge of corpus spongiosum; and complete transection of the urethra (Fig. 1A and B). The lacerations were repaired, and the urethra was reanastomosed

over an 18-F Silastic Foley catheter. The immediate postoperative result was satisfactory, but a wedge of the ventral portion of the glans subsequently necrosed and sloughed. The final cosmetic result, however, was acceptable to the patient (Fig. 1C and D).

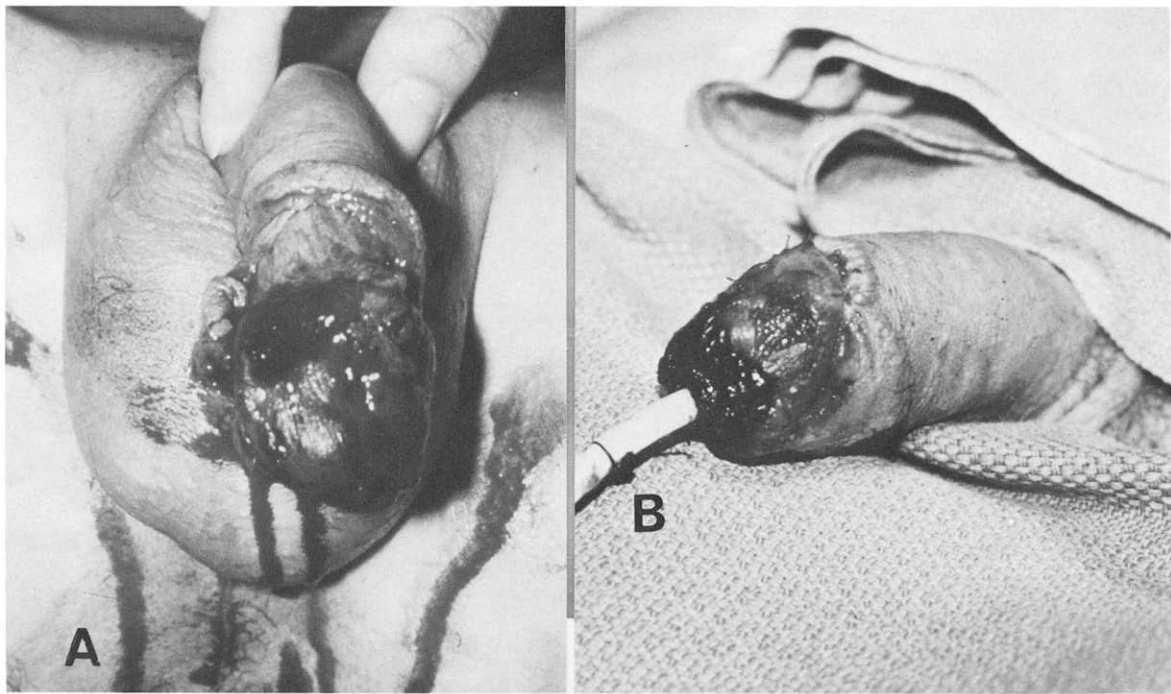


FIGURE 2. (Case 5). (A) Preoperative photograph revealing circumferential lacerations of penile skin and laceration of right corpus cavernosum. (B) Postoperative photograph with urethral catheter in place. Black necrotic area is visible on distal third of glans penis. This area subsequently sloughed, and slightly hypospadiac meatus resulted.

#### Case 4

A fifteen-year-old male student sustained multiple lacerations after inserting his erect penis directly into a canister-type vacuum cleaner. Examination revealed multiple irregular lacerations of the foreskin and glans penis; one laceration also involved the urethral meatus. The lacerations were repaired, and a urethral catheter was inserted and left for ten days. Postoperatively, the patient experienced meatal stenosis, which periodically requires dilation.

#### Case 5

A twenty-one-year-old male student sustained partial avulsion of the glans penis and laceration of the right corpus cavernosum and urethra while masturbating with an electric broom (Fig. 2A). The patient first stated that his penis had been caught and injured by an electric fan as he walked past it nude. His lacerations were repaired; a urethral catheter was inserted, and a suprapubic cystostomy was performed. The urethral catheter was removed on the seventeenth postoperative day. Unfortunately, the distal portion of the glans penis sloughed in the postoperative period and a

minimally hypospadiac urethral meatus resulted (Fig. 2B).

#### Comment

Vacuum cleaner injuries to the penis were first described by Fox and Barrett in 1960.<sup>20</sup> Since that time there have been several additional case reports, primarily in the British literature, documenting similar injuries.<sup>21,22</sup> Only 2 cases have been presented in the United States literature, in the form of letters to the editor. This brings the total number of previously reported cases to 13.<sup>23,24</sup>

The patients' ages have ranged from twenty-eight to seventy-five years, all but 2 patients having been more than fifty years old. This observation prompted the suggestion that autostimulation by means of a vacuum cleaner represents a bizarre method of masturbation adopted by elderly men. Four of the five patients reported herein were under twenty-one years of age, and so these cases do not substantiate this notion.

Penile injuries from vacuum cleaners range in severity from edema, ecchymosis, and minimal lacerations that are not extensive enough to warrant suture,<sup>20</sup> to degloving injuries requiring split-thickness skin grafting,<sup>21</sup> and up to

extensive lacerations of the glans, penile shaft, corpora cavernosa, and urethra.<sup>20,22</sup> The more severe injuries can result in subsequent penile deformity and urethral strictures. Our Case 2 represents the only case of complete avulsion and loss of the glans which has been reported, but partial avulsion is not uncommon and was noted in 2 additional cases (Cases 3 and 5). Only 1 patient previously reported was noted to have a urethral injury, which was treated with a two-stage urethroplasty.<sup>22</sup> Four patients in the present series sustained urethral lacerations (other than the meatus) requiring repair. In 2 patients (Cases 3 and 5) there was subsequent loss of a portion of the glans, resulting in a minimally hypospadiac meatus. All patients retain their potency.

The majority of the reported injuries were sustained when the erect penis was placed directly into the body of the vacuum cleaner or electric broom where the fan blades are located, approximately 15 cm from the inlet. However, severe avulsion and degloving injuries can also occur when the penis is placed in the vacuum cleaner hose, as in Case 2.

The fact that 5 patients were found to have vacuum cleaner injuries to the penis in the past twenty years in a town of approximately 50,000 persons suggests that this may be a more common injury than was supposed. Most patients will attempt to fabricate a plausible story to explain their penile injury, but the majority, on closer questioning, will eventually relate the truth. Perhaps the true cause of many penile injuries goes unrecorded in busy metropolitan emergency rooms, and this may account for the paucity of reported cases.

Another reason for suspecting that vacuum cleaner injuries may be more common than reported is the apparent interest in this form of masturbation as recorded in the sexually oriented popular magazines.<sup>25</sup> It was brought to our attention that testimonials as to the satisfactory nature of autostimulation with the use of a vacuum cleaner are not uncommon. Even more alarming are published statements such as, "In all the times I have done this [masturbated with a vacuum cleaner], I have experienced no harm or injury."<sup>25</sup>

The cases presented demonstrate the very real danger that this form of masturbation in-

volves. In addition, it is likely that autostimulation by means of vacuum cleaners and the penile trauma subsequent to their use are much more common than is generally appreciated.

Mayo Clinic  
200 First Street SW  
Rochester, Minnesota 55905

#### References

1. Brown JB, and Fryer MP: Penoscrotal skin losses, repaired by implantation and free skin grafting: report of known normal offspring (preliminary report on total and deep losses), *Ann Surg* 145: 656 (1957).
2. Cullen TH: Avulsion of the skin of the penis and scrotum, *Br J Urol* 38: 99 (1966).
3. Sharma LK, Koshal A, and Prakash A: Degloving injury of the penis, *Int Surg* 58: 648 (1973).
4. Sangmit S: Reconstruction of the penoscrotal skin after avulsion, *ibid* 60: 563 (1975).
5. Tanga MR, and Kawathekar P: Injury due to bull goring, *ibid* 58: 635 (1973).
6. McRoberts JW, Chapman WH, and Ansell JS: Primary anastomosis of the traumatically amputated penis: case report and summary of literature, *J Urol* 100: 751 (1968).
7. Mendez R, Kiely WF, and Morrow JW: Self-emasculation, *ibid* 107: 981 (1972).
8. Cohen BE, May JW Jr, Daly JSF, and Young HH II: Successful clinical replantation of an amputated penis by microneurovascular repair: case report, *Plast Reconstr Surg* 59: 276 (1977).
9. Hall DC, Lawson BZ, and Wilson LG: Command hallucinations and self-amputation of the penis and hand during a first psychotic break, *J Clin Psychiatry* 42: 322 (1981).
10. Flowerdew R, Fishman IJ, and Churchill BM: Management of penile zipper injury, *J Urol* 117: 671 (1977).
11. Kerry RL, and Chapman DD: Strangulation of appendages by hair and thread, *J Pediatr Surg* 8: 23 (1973).
12. Summers JL, and Guira AC: Hair strangulation of the external genitalia: report of two cases, *Ohio State Med J* 69: 672 (1973).
13. Farah R, and Cerny JC: Penis tourniquet syndrome and penile amputation, *Urology* 2: 310 (1973).
14. Thomas AJ Jr, Timmons JW, and Perlmutter AD: Progressive penile amputation: tourniquet injury secondary to hair, *ibid* 9: 42 (1977).
15. Markland C, and Merrill D: Accidental penile gangrene, *J Urol* 108: 494 (1972).
16. Mofenson HC: Penile trauma (letter to the editor), *JAMA* 225: 1388 (1973).
17. Dakin WB: *Urological Oddities*. Los Angeles, Univ. of California Publ., 1948, pp. 199-235.
18. Stuppler SA, Walker JC, Kandzari SJ, and Milam DF: Incarceration of penis by foreign body, *Urology* 2: 308 (1973).
19. Schellhammer P, and Donnelly J: A mode of treatment for incarceration of the penis, *J Trauma* 13: 171 (1973).
20. Fox M, and Barrett EL: "Vacuum cleaner injury" of the penis, *Br Med J* 1: 1942 (1960).
21. Hill JT: Penile injuries from vacuum cleaners (letter to the editor), *Br Med J* 281: 519 (1980).
22. Citron ND, and Wade PJ: Penile injuries from vacuum cleaners, *ibid* 281: 26 (1980).
23. Zufall R: Laceration of penis from hand vacuum cleaner (letter to the editor), *JAMA* 224: 630 (1973).
24. Forrest JB, and Gillenwater JY: The hand vacuum cleaner: friend or foe? (letter to the editor), *J Urol* 128: 829 (1982).
25. Penthouse Forum, March 1975, pp. 30-32.